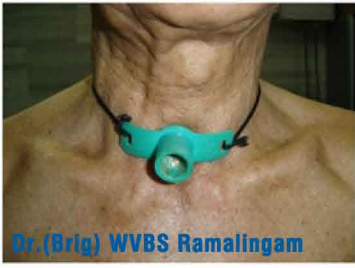


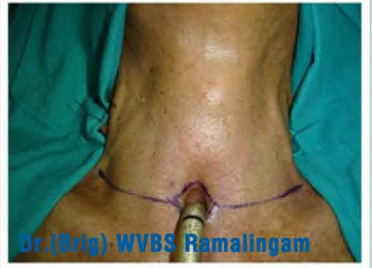
## Laryngo-Tracheal Stenosis



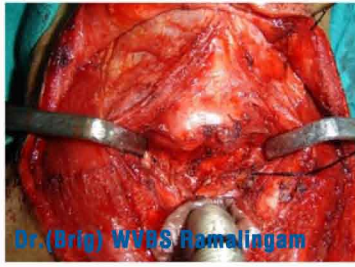Dr.(Brig) WVBS Ramalingam

Patient on tracheostomy



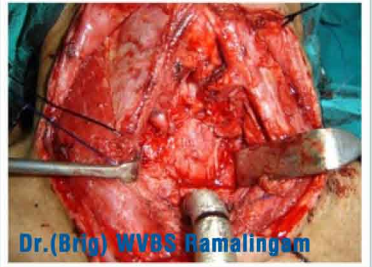Dr.(Brig) WVBS Ramalingam

Neck incision



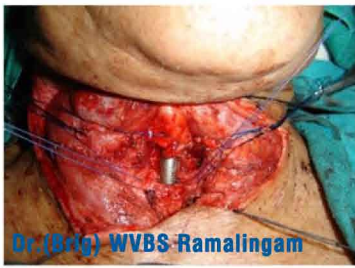Dr.(Brig) WVBS Ramalingam

Stenotic segment Exposed



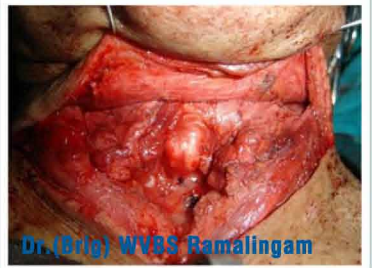
Dr.(Brig) WVBS Ramalingam

Stenotic segment excised



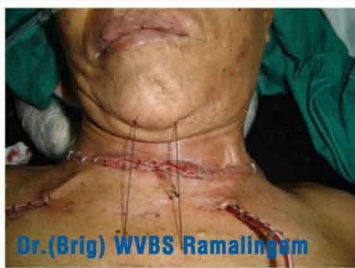Dr.(Brig) WVBS Ramalingam

Anastomosis in progress



Dr.(Brig) WVBS Ramalingam

Anastomosis in progress



Dr.(Brig) WVBS Ramalingam

Post op pic